

Odontogenic Cysts in Port Harcourt, Nigeria: a 10-year retrospective Study

*Cornelius Azekanabo IYOGUN, * Efetobo Victor ORIKPETE, **Adaeze Augusta MBAGWU, *Olufemi Gbenga OMITOLA

[*Department of Oral Pathology & Biology, University of Port Harcourt, Port Harcourt, Rivers State, Nigeria

**Department of Child Dental Health, University of Port Harcourt Teaching Hospital, Port Harcourt, Rivers State, Nigeria]

Correspondence

Dr. EV Orikpete

Department of Oral Pathology & Biology

Faculty of Dentistry, College of Health Sciences

University of Port Harcourt

Port Harcourt, Rivers State, Nigeria.

Email: efezizooo@yahoo.com

ABSTRACT

Objective: Odontogenic cysts are cysts derived from the tooth-forming apparatus, and are frequently encountered in dental practice. The aim of this study was to evaluate and describe the pattern of occurrence of odontogenic cysts in the University of Port Harcourt Teaching Hospital (UPTH) Port Harcourt, South-South Nigeria.

Methods: This was a 10-year (January, 2009 to December 2018) retrospective review of histologically diagnosed cases of odontogenic cysts at UPTH. The age, gender, site and histopathological diagnosis was recorded for each case. The histology slides were retrieved and reviewed to confirm the initial diagnosis. Data analysis was done using SPSS version 23 software (IBM Corp., 2015).

Results: Odontogenic cysts accounted for 52 (10.4%) of the total number of 499 histologically diagnosed orofacial lesions seen during the period under review. Patients age ranged from 4 to 68 years, with a mean age of 26.7 ± 14.9 years, and a peak in the third (n=19; 36.5%) decade of life. There was no gender predilection, and the mandible was the most common site.

Dentigerous cyst was the most frequently diagnosed odontogenic cyst (n= 34; 65.4%). It was seen mostly in the second (n=9; 26.5%) and third (n=13; 38.2%) decades of life, with a mean age of 24.6 ± 13.3 years. There was an equal gender distribution, and the mandible (n=25; 73.5%) was the most common site. Radicular cyst was the second most common odontogenic cyst (n=10; 19.2%), while odontogenic keratocyst was the third most common (n=5; 9.6%). Less frequently encountered odontogenic cysts in this study were glandular odontogenic cyst (n=2; 3.8%) and calcifying odontogenic cyst (n=1; 1.9%).

Conclusion: This study found dentigerous cyst to be the most common odontogenic cyst, similar to most reports from Nigeria and sub-Saharan Africa, though contrary to reports from other parts of the world. Other findings are essentially in keeping with global trend.

Keywords: odontogenic, cysts, retrospective study, Nigeria

Citation: Iyogun CA, Orikpete EV, Mbagwu AA, Omitola OG. Odontogenic Cysts in Port Harcourt, Nigeria: a 10-year retrospective study. *Nig J Dent Res* 2020; 5(1):1-6.

INTRODUCTION

Odontogenic cysts (OCs) are jaw cysts that are lined by epithelium that is derived from tooth forming apparatus. They are subclassified as developmental or inflammatory in origin. The inciting factors that initiate the formation of developmental cysts are

largely unknown, whereas inflammatory cysts are the result of inflammation initiated by pulp necrosis.¹ Radicular cyst (RC), dentigerous cyst (DC) and odontogenic keratocyst (OKC) are the most frequently encountered odontogenic cysts of the jaws.²⁻⁴ Other less commonly seen OCs include

calcifying odontogenic cyst, gingival cyst of the newborn, gingival cyst of the adult, developmental lateral periodontal cyst and glandular odontogenic cyst.

Radicular (periapical) cyst is an inflammatory odontogenic cyst, and has been reported to be the most common of the odontogenic cysts.³ It derives its epithelial lining from the proliferation of small odontogenic epithelial residues (rests of Malassez) within the periodontal ligament.² Its peak occurrence is between the third and sixth decades of life, with males being more frequently affected than females. Radicular cyst occurs most frequently in the anterior maxilla, and is associated with a non-vital tooth.³ It is usually asymptomatic, unless there is an acute inflammatory exacerbation, in which case swelling and pain may be noted.¹

Dentigerous (follicular) cyst is a developmental odontogenic cyst. It is the second most common cyst of odontogenic origin, and the most common developmental odontogenic cyst.^{4,3} It develops from proliferation of enamel organ remnants or reduced enamel epithelium. It is associated with the crown of an unerupted tooth, usually the mandibular/maxillary third molars, maxillary canine or mandibular second premolar.³ It is seen mostly in the 2nd and 3rd decades of life, and the mandible is more frequently affected.³ Small dentigerous cysts are usually asymptomatic. When large, they may be associated with bone expansion.

Odontogenic keratocyst (OKC) is a developmental odontogenic cyst that arises from cell rests of the dental lamina. Varying frequencies have been reported in the literature, ranging between 2.5 – 21.8% of all odontogenic cysts.³ It may be found in patients who range in age from infancy to old age but seen mostly in the 2nd and 3rd decades of life.⁵ There is a slight male predilection. It is commoner in the mandible; posterior portion of body and ramus region most affected.⁵ Most cases are asymptomatic, with jaw swelling being a particularly late feature of OKC, because it preferentially grows in an antero-posterior direction within the bone.⁵

The reported prevalence of odontogenic cysts in the scientific literature shows a wide range, from as low as 0.8%. to as high as 45.9%.⁴ Studies from Nigeria and other parts of Sub-Saharan African have shown a much lower prevalence compared to Caucasian studies.^{4,6-11} There appears to be paucity of data on odontogenic cysts from the South-South geopolitical region of Nigeria. The aim of this study was to describe the pattern of occurrence of odontogenic

cysts in Port Harcourt, one of the most densely populated cities in the South-South geopolitical region of Nigeria.

MATERIALS AND METHODS

The records of all histologically diagnosed cases in the Department of Oral Pathology & Biology, University of Port Harcourt Teaching Hospital from January, 2009 to December 2018 were retrieved from the clinical and histopathology registers. Cases of odontogenic cysts were selected from these, and the age, gender, site and histopathological diagnosis was recorded for each case. The histology slides of all cases of odontogenic cysts were retrieved, and reviewed to confirm the initial diagnosis. In cases where the initial histology slides were missing, damaged or of poor quality, the formalin-fixed paraffin embedded tissue blocks were retrieved. New histological slides were made by cutting 4 µm thick sections using a microtome and staining with haematoxylin and eosin. The new tissue slides were examined independently by two Oral pathologists. All cases in which the diagnosis was equivocal, were excluded from the study. Data analysis was done using SPSS version 23 software (IBM Corp., 2015).

RESULTS

A total number of 499 orofacial lesions were submitted for histological diagnosis at the Department of Oral Pathology & Biology, University of Port Harcourt Teaching Hospital over the duration of the study. Of these, there were fifty-two cases of odontogenic cysts, giving a prevalence of 10.4%. Patients age ranged from 4 to 68 years, with a mean age of 26.7 ± 14.9 years, and a peak in the third (n=19; 36.5%) decade of life (Table 1). There was no gender predilection. The mandible was involved more often than the maxilla, with ratio of 1.9:1 (Table 2).

Dentigerous cyst was the most frequently diagnosed odontogenic cyst (n= 34; 65.4%) (Figure 1). It was seen mostly in the second (n=9; 26.5%) and third (n=13; 38.2%) decades of life, with a mean age of 24.6 ± 13.3 years. There was an equal gender distribution, and the mandible (n=25; 73.5%) was the most common site. Radicular cyst was the second most common odontogenic cyst in this study, accounting for 10 (19.2%) cases (Figure 2). It had a bimodal peak in the third (n=3; 30.0%) and sixth (n=3;30.0%) decades of life, with a mean age of 30.1 ± 18.9 years. It was twice as common in males (n=7; 70%), and the maxilla was affected more often than the mandible in a ratio of 3:2

Odontogenic Cysts in Port Harcourt, Nigeria..

Table 1: Relative frequency and age distribution of odontogenic cysts

Histopathological Diagnosis	Age group (in years)							Total	Relative frequency
	0-9	10-19	20-29	30-39	40-49	50-59	60-69		
Dentigerous cyst	3	9	13	6	0	2	1	34	65.4%
Radicular cyst	2	1	3	0	1	3	0	10	19.2%
Odontogenic keratocyst	0	0	3	1	0	0	1	5	9.6%
Glandular odontogenic cyst	0	0	0	2	0	0	0	2	3.8%
Calcifying odontogenic cyst	0	1	0	0	0	0	0	1	1.9%
Total	5	11	19	9	1	5	2	52	100.0%

Table 2: Site and gender distribution of odontogenic cysts

Histopathological Diagnosis	Gender	Site		Total
		Mandible	Maxilla	
Dentigerous cyst	Male	13	4	17
	Female	12	5	17
Radicular cyst	Male	3	4	7
	Female	1	2	3
Odontogenic keratocyst	Male	2	0	2
	Female	1	2	3
Glandular odontogenic cyst	Male	0	0	0
	Female	2	0	2
Calcifying odontogenic cyst	Male	0	0	0
	Female	0	1	1
Total		34	18	52

Odontogenic keratocyst was the third most frequent odontogenic cyst (Figure 3). It had a peak in the third decade of life (n=3; 60.0%) and a mean age of occurrence of 34.4 ± 18.1 years. There was a female predilection (n=3; 60.0%), and the mandible (n=3;

60.0%) was more commonly involved than the maxilla. Other cysts seen in this study were glandular odontogenic cyst and calcifying odontogenic cyst. (Table 1) (Figure 4)

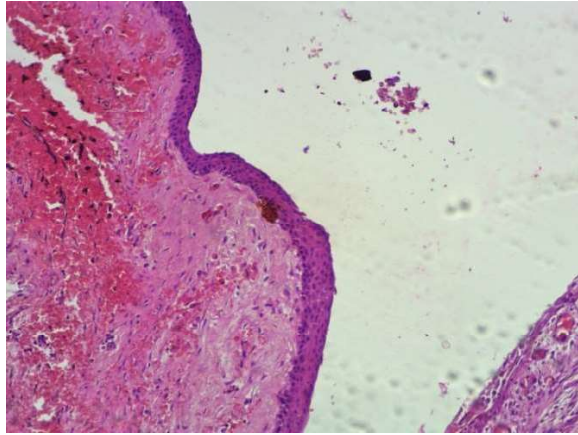


Figure 1. Dentigerous cyst showing a non-keratinized stratified squamous epithelial lining. (x 100 magnification)

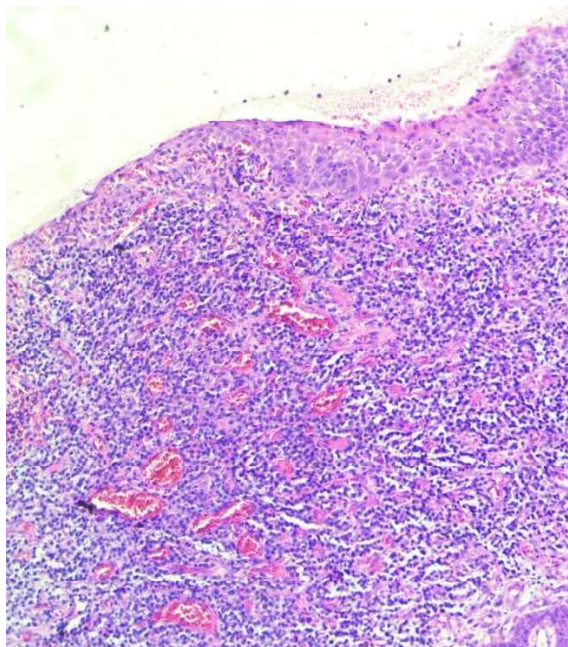


Figure 2. Radicular cyst showing a non-keratinized stratified squamous epithelial lining, with marked chronic inflammatory cell infiltration of the capsule. (x 100 magnification)

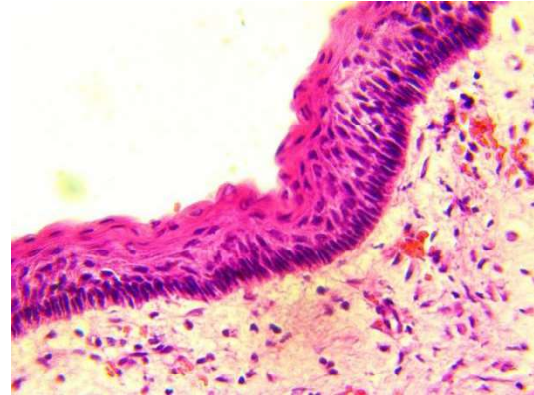

Figure 3. Odontogenic keratocyst showing a parakeratinized stratified squamous epithelial lining. The basal cells are columnar, with palisaded hyperchromatic nuclei (x 400 magnification)

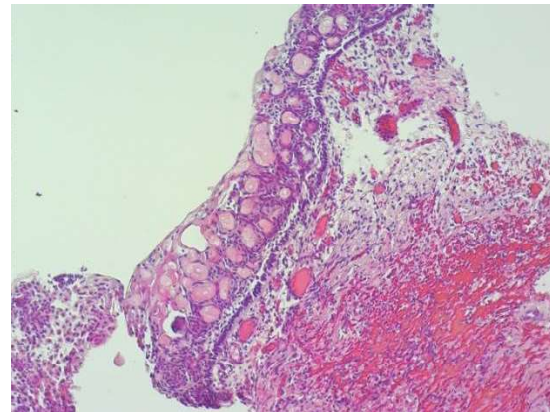


Figure 4. Calcifying odontogenic cyst showing a stratified squamous epithelial lining. There is abundant ghost cell keratinization of the epithelium (x 100 magnification)

DISCUSSION

A total of fifty-two cases of odontogenic cysts were documented in this 10-year review. Other Nigerian and African studies have reported similar low figures. In Ibadan (South-Western Nigeria), 65 cases were documented over a 14-year period⁸, in Kano (Northern Nigeria)²² 43 cases were documented in a 7-year study, while Oji⁶ reported 16 cases of odontogenic cysts out of a total of 20 oral cysts seen over a 10-year period in Enugu (South-Eastern Nigeria). Butt et al reported 111 odontogenic cysts in Kenya over a 19-year period.⁹ This contrasts with results of studies in Caucasians, with Jones et al reporting 7121 in a 30-year study in an English population.²³ Açikgöz et al documented 459 odontogenic cysts in a Turkish population over a 9-year period.⁴ Most Nigerian studies have recorded

few cases of histologically diagnosed odontogenic cysts. This may be the result under-diagnosis, under-reporting and underutilization of dental/histopathological services. The majority of odontogenic cysts are asymptomatic, and are discovered when jaw radiographs are taken for routine purposes, or for other unrelated conditions. Many Nigerians seek dental care only when there is pain.¹⁴ As such, many cases of odontogenic cysts of the jaws remain undiagnosed. Also, patronage of non-professionals, may account for the low incidence of odontogenic cysts. Furthermore, there is under-reporting of cases of odontogenic cysts, due to the low levels of utilization of histopathology services in this part of the world. Many cases of odontogenic cysts are diagnosed on clinical and radiographic basis, and treated without submission of specimen for confirmatory histopathological diagnosis.

Even though the number of OCs encountered in Nigerian studies is small, the prevalence among diagnosed orofacial cases compares favourably with the findings of other authors. This study documented a 10.4% prevalence of OCs, comparable to the findings of Ochsenius et al (10%), Jones et al (12.8%) and El Gehani et al (14.8%)^{13,15,16}

Overall, this study showed that odontogenic cysts were most frequent in the second and third decades of life, affected the mandible more than the maxilla, and have no gender bias. This is largely in consonance with the findings of other authors.¹⁷ However, most previous reports have documented odontogenic cysts to be more common in males.¹⁷

Dentigerous cyst was the most frequent OC in this study. This is similar to the findings of Ogunlewe et al., Oji and Iyogun et al. in previous Nigerian studies.^{6,7,20} Similarly, Butt et al and Ramachandra et al found DCs to be the commonest OC in a Kenyan and Indian population respectively.^{9,18} This may be attributed to the fact that many cases of radicular cysts are not sent for histopathological examination following tooth extraction because the diagnosis is often clinically obvious. The mean age of DCs in this study was 24.6 years. This is similar to the 24.9 years reported by Ansari et al.¹⁷ The second and third decades were the peak age groups affected by dentigerous cysts in this study, similar to most reports in the literature.^{4,9,20} There was no gender predilection, contrary to most reports in the literature which found a male predominance.^{4,6,9,21} The mandible was more commonly involved than the maxilla, similar to reports in the literature.^{6,10}

Radicular cyst was the second most common OC in this study, contrary to most reports in the literature in which it was the most common.^{6,15} This may be attributed to the fact that many cases of radicular cysts are not sent for histopathological examination following tooth extraction because the diagnosis is often clinically obvious. Male predominance was noted, and the maxilla was affected more often than the mandible. This is in agreement with previous reports.^{6,16}

Odontogenic keratocysts in this study was the third most common OC. It was encountered mostly in the third decade, with more mandibular involvement.^{4,13} These findings largely corroborate previous reports in the literature. The female predilection for OKC seen in this study is similar to the findings of Lawal et al, Chirapathomsakul et al and Acikgoz et al.^{4,22,23} It is however at variance with the findings of most other studies, in which a male predilection was noted.^{3,19}

CONCLUSION

This study found the prevalence of odontogenic cysts to be 10.4%. They were seen mostly in the third decade, with a mean age of 26.7 ± 14.9 years. The mandible was the most common site, and no gender predilection was recorded. Dentigerous cyst was the most common odontogenic cyst, accounting for 65.4% of cases, with a mean age of 24.6 ± 13.3 years. Radicular cyst and odontogenic keratocyst were the second and third most common odontogenic cyst respectively.

ACKNOWLEDGEMENT

We would like to thank the staff of the department of Oral Pathology and Biology, University of Port Harcourt for their co-operation and support.

REFERENCES

1. Neville BW, Damm DD, Allen CM, Chi AC. Oral and maxillofacial pathology. 4th ed. Canada: Elsevier; 2015.
2. Regezi JA, Sciubba JJ, Jordan RC. Odontogenic tumours. In: Oral pathology: clinical pathologic correlations. Missouri: Elsevier. 2012; 273-274.
3. Shear M, Speight PM. Cysts of the oral and maxillofacial regions, 4th Edition, Oxford, UK: Blackwell Munksgaard; 2007.
4. Acikgoz A, Uzun-Bulut E, Ozden B, Gunduz K. Prevalence and distribution of odontogenic and nonodontogenic cysts in a Turkish population.

- Med Oral Patol Oral Cir Bucal. 2012; 17(1): e108–115.
5. El-Naggar AK, Chan JKC, Grandis JR, Takata T, Slootweg PJ (Eds). Odontogenic and maxillofacial bone tumours. In: WHO Classification of Head and Neck Tumours (4th edition). IARC: Lyon 2017.
 6. Oji CH. Statistical observations on jaw cysts in Enugu, Nigeria 1987-96. *Odontol Stomatol Trop* 1999; 22(85):33-36.
 7. Ogunlewe MO, Odukoya O, Akinwande JA. Epithelial jaw cysts: analysis of 126 Nigerian cases. *Afr Dent J*. 1996; 10:1-9.
 8. Arotiba JT, Lawoyin JO, Obiechina AE. Pattern of occurrence of odontogenic cysts in Nigerians. *East Afr Med J* 1998; 75:664-666.
 9. Butt FM, Ogeng'o J, Bahra J, Chindia ML. Pattern of odontogenic and non-odontogenic cysts. *J Craniofac Surg* 2011; 22:2160-2162.
 10. Iyogun CA, Ochicha O, Sule AA, Adebola RA. Jaw Cysts in Kano: Northern Nigeria. *Int J Oral Maxillofac Pathol*; 2013;4(3):08-12.
 11. Nunez-Urrutia S, Figueiredo R, Gay-Escoda C. Retrospective clinicopathologic study of 418 odontogenic cysts. *Med Oral Patol Oral Cir Bucal* 2010; 15:E767YE773
 12. Iyogun C A, Sule AA, Omitola O G, Relative prevalence of odontogenic cysts and tumours in Kano, Northern Nigeria. *J Dental Oral Health* 2017;3(1):
 13. Jones AV, Craig GT, Franklin CD. Range and demographics of odontogenic cysts diagnosed in a UK population. *J Oral Pathol Med*. 2006; 35:500-507.
 14. Ajayi DM, Arigbede AO. Barriers to oral health care utilization in Ibadan, South West Nigeria. *Afr Health Sci*. 2012; 12(4):507-513
 15. Ochsenius G, Escobar E, Godoy L, Peñafiel C. Odontogenic Cysts: Analysis of 2.944 cases in Chile. *Med Oral Patol Oral Cir Bucal* 2007;12: E85-91.
 16. El Gehani R, Krishnan B, Orafi H, The prevalence of inflammatory and developmental odontogenic cysts in a Libyan population. *Libyan J Med* 2008; 3:75-77.
 17. Ansari SR, Rehman A, Rehman B. Frequency and demographic of commonly occurring odontogenic cysts in Khyber, Pakhtankhwa (Pakistan). *Pak Oral Dent J* 2010; 30:41-46
 18. Ramachandra S, Shekar PC, Prasad S, Kumar KK, Reddy GS, Prakash KL, *et al*. Prevalence of odontogenic cysts and tumours: A retrospective clinico-pathological study of 204 cases. *SRM J Res Dent Sci* 2014; 5:170-173.
 19. Meningaud J, Oprean N, Pitak-Arnop P, Bertrand J. Odontogenic cysts: a clinical study of 695 cases. *J Oral Sci*. 2006; 48(2): 59–62.
 20. Bhushan NS, Rao NM, Navatha M, Kumar BK. Ameloblastoma arising from a dentigerous cyst-a case report. *J Clin Diagn Res* 2014; 8(5):ZD23-25.
 21. Baghaei F, Zargaran M, Najmi H, Moghimbeigi A. A clinicopathological study of odontogenic cysts and tumors in Hamadan, Iran. *J Dent (Shiraz)*. 2014; 15(4):167-172.
 22. Lawal AO, Adisa AO, Sigbeku OF. Cysts of the oro-facial region: A Nigerian experience. *J Oral Maxillofac Pathol*. 2012; 16:167-171.
 23. Chirapathomsakul D, Sastravaha P, Jansisyantont P. A review of odontogenic keratocysts and the behavior of recurrences. *Oral Surg, Oral Med, Oral Pathol, Oral Radiol, Endod*. 2006; 101 (1):5-9.